

From Recurrence to Complete Healing: Innovative Ksharsutra Therapy as an Emerging Aid for Global Healthcare — a Case Study of Antibiotic-Resistant Scrotoanal Fistula

Dr. Sandipa Channawar¹, Dr. Jyoti Shinde² Dr. Pranav Naikwade³

¹PG Scholar, Department of Shalyatantra, Shri Ayurved Mahavidyalaya, Hanuman nagar, Nagpur

² HOD and Professor, Department of Shalyatantra, Shri Ayurved Mahavidyalaya, Hanuman nagar, Nagpur

³ Associate Professor, Department of Shalyatantra, Shri Ayurved Mahavidyalaya, Hanuman nagar, Nagpur

BACKGROUND: *Bhagandara* (fistula-in-ano) is described in Ayurveda as one of the *Ashtamahagada* (eight dreadful diseases) by *Acharya Sushruta*, owing to its chronicity, recurrence, and associated complications. In modern clinical terms, this corresponds to fistula-in-ano, a disease notorious for recurrence even after surgical intervention. Among its variants, the scrotoanal fistula represents a rare and complex form, characterized by an atypical tract course involving the scrotum, frequent sphincter involvement, and increased risk of recurrence. Innovations in *Shalyatantra*, particularly *Ksharasutra therapy*, provide a minimally invasive, effective, and globally recognized alternative for fistula management. **Aim:** To assess the effectiveness of *Shalyatantra* innovations in Ayurveda, especially *Ksharasutra* therapy, in the management of complex scroto-anal fistula. **Objective:** To evaluate the efficacy of *Ksharasutra* therapy combined with *Jatyadi Taila* application and internal *Panchatikta Ghrita Guggulu* in antibiotic-resistant scrotoanal fistula achieving complete healing. **Methodology:** A 60-year-old male patient with a history of incision and drainage (I&D) of a left perianal abscess, which subsequently recurred and progressed into a complex scroto-anal fistula, was managed with Ayurvedic surgical innovation. The patient underwent partial fistulectomy followed by application of *Apamarga Ksharasutra*. Postoperatively, local wound care was carried out with *Jatyadi Taila* dressings, while *Panchatikta Ghrita Guggulu* was administered internally. **Monitoring:** Weekly and biweekly evaluations were performed using standardized wound assessment criteria: *Vrana Strava* (discharge), *Vrana Akrti* (wound size/volume), *Vrana Varna* (granulation), Slough, pain, and odour until complete wound healing was achieved. Healing rate (cm^3/week) and Unit Healing Time (days/cm) were calculated. Statistical analysis was performed using the Wilcoxon Signed-Rank Test **Results:** All three wounds healed completely with 100% reduction in discharge, wound size, and slough and healthy granulation achieved. Healing rates were **4.38–10.5 cm^3/week** , while Unit Healing Time ranged from **16.8–22.2 days/cm**, demonstrating effective controlled cutting and healing with *Ksharasutra* therapy. **Conclusion:** *Ksharasutra* therapy with Ayurvedic wound care achieved complete healing of recurrent, antibiotic-resistant scroto-anal fistula without recurrence. These findings highlight Ayurveda's innovative role in managing complex surgical conditions and its potential as an emerging aid for global healthcare.

Keywords: *Ksharasutra*; *Bhagandara*; Scrotoanal fistula; *Jatyadi Taila*; Unit Healing Time

INTRODUCTION:

Bhagandara (fistula-in-ano) is described in *Ayurvedic Shalyatantra* as one of the most challenging disorders due to its chronicity, recurrent suppuration, and tendency to form multiple tracts. Acharya Sushruta classifies Bhagandara among the *Ashtamahagada*—a group of eight grave and obstinate diseases—highlighting its difficult prognosis and high recurrence potential.¹ The pathogenesis (*samprapti*) is explained as the vitiation of *doshas* leading to the formation of *pidaka* (abscess) near the guda, which on bursting transforms into a fistulous tract.² Classical texts also enumerate clinical features such as pain, swelling, discharge, foul smell, and recurrent abscess formation, which correlate with modern manifestations.³ Sushruta further classifies Bhagandara into five types—*Shataponaka*, *Parisravi*, *Shambukavarta*, *Uttara*, and *Unmargi*—each representing different tract patterns and prognostic significance.⁴ Management principles are described extensively in *Shalyatantra*, recommending *shastrakarma* (surgery), *ksharakarma* (alkaline cauterization), *agnikarma* (thermal cauterization), and *ksharasutra chikitsa* (medicated seton therapy) to ensure proper excision, drainage, debridement, and wound healing.⁵ Vagbhata emphasizes that Kshara can be superior to surgical intervention in certain chronic conditions, underscoring its importance in anorectal disorders.⁶ Additionally, principles of *vrana chikitsa* described by Charaka help guide comprehensive wound management in chronic conditions such as fistula-in-ano.⁷

In modern clinical practice, fistula-in-ano is defined as a chronic abnormal communication between the anal canal and the perianal skin, usually developing as a sequela to anorectal abscess formation.⁸ The most widely accepted mechanism is the cryptoglandular theory, where obstruction of the anal glands leads to bacterial infection, abscess formation, and persistence of the tract after spontaneous or surgical drainage.⁹ Fistulas may be simple or complex depending on tract involvement, with variants such as intersphincteric, transsphincteric, suprasphincteric, and extrasphincteric pathways described in Parks' classification.¹⁰ Patients typically present with persistent seropurulent discharge, pain during defecation or sitting, swelling, itching, foul smell, and recurrent abscess formation.¹¹ Complex cases may involve multiple external openings, horseshoe extensions, or atypical routes such as scrotoanal extension.¹² MRI fistulography is considered the gold standard for evaluating complex tracts, aiding in preoperative mapping.¹³ Conventional treatments—fistulotomy, fistulectomy, seton placement, advancement flap repair, and sphincter-sparing procedures like LIFT—remain widely practiced but are associated with significant limitations including recurrence, postoperative incontinence, delayed wound healing, and impaired quality of life.¹⁴ These challenges become more pronounced in high or branching fistulas with sphincter involvement and in conditions complicated by antibiotic-resistant infections, leading to repeated abscess formation and persistent non-healing tracts even after surgical interventions.¹⁵

Complex fistula-in-ano is considered one of the most challenging proctologic conditions due to its variable anatomy, secondary extensions, and frequent involvement of the sphincter muscles.¹⁶ High transsphincteric, suprasphincteric, horseshoe, and atypical variants such as scrotoanal fistulas make

complete tract eradication technically demanding while increasing the risk of postoperative continence impairment.¹⁷ Persistent sepsis, multiple external openings, chronic inflammation, and fibrosis further delay wound healing and contribute to recurrence.¹⁸ Despite advancements in colorectal surgery, recurrence remains a major concern: simple fistulas recur in 5–15%, whereas complex fistulas show recurrence rates ranging from 20–40%; in Crohn’s disease or atypical, long-tract fistulas, recurrence may exceed 50%.¹⁹ The global incidence of fistula-in-ano is estimated at 1.2–2.8 per 10,000 population annually, with a higher incidence noted in males and in individuals with recurrent anorectal abscesses.²⁰ Major contributors to recurrence include failure to identify the internal opening, unrecognized secondary tracts, inadequate drainage of infection, and postoperative sphincter dysfunction.²¹ These challenges underscore the urgent need for reliable, sphincter-preserving, and recurrence-reducing alternatives in the management of chronic and complex fistulas.

Given the high recurrence rates, anatomical complexity, and limitations of conventional surgical approaches, there is a growing need for alternative, effective, and globally adaptable modalities in the management of complex and antibiotic-resistant fistulas. Ksharasutra therapy, validated through classical Ayurvedic literature and modern clinical research, emerges as a scientifically proven, minimally invasive, sphincter-preserving technique with demonstrated efficacy in both simple and complex anal fistulas.²² The method has been standardized by CCRAS and shown to offer controlled chemical debridement, sustained antimicrobial action, and uniform tract obliteration, making it superior to conventional surgery in preventing premature closure and recurrence.²³ Studies have highlighted its effectiveness even in high, recurrent, and branching fistulas—variants in which modern surgical procedures often face limitations.²⁴ Its ability to treat long, tortuous, or atypical routes such as scrotoanal fistulas without compromising anal continence further underscores its clinical relevance.²⁵ At a global level, the increasing burden of antibiotic resistance and chronic perianal sepsis necessitates minimally invasive, cost-effective, and reproducible therapies that address both infection and tract healing simultaneously.²⁶ In this context, Ksharasutra therapy represents a promising contribution from Ayurvedic Shalyatantra to modern global healthcare, aligning with WHO’s call for effective non-antibiotic strategies in infectious disease management.²⁷ The present case study exemplifies this potential by demonstrating complete healing of a recurrent, antibiotic-resistant scrotoanal fistula through an integrative Ayurvedic approach.

AIM AND OBJECTIVES:

Aim: To assess the effectiveness of *Shalyatantra* innovations in Ayurveda, especially *Ksharasutra* therapy, in the management of complex scrotoanal fistula.

Objective: To evaluate the efficacy of *Ksharasutra* therapy combined with *Jatyadi Taila* application and internal *Panchatikta Ghrita Guggulu* in antibiotic-resistant scrotoanal fistula achieving complete healing.

CASE PRESENTATION:

A 60 year old male patients presented in our OPD with the complaints of wound at right perianal region since 8 months, boil at base of scrotum and left perianal region since 3 months, pus discharge from boil site since 3 months and unable to sit since 1 month. He was known case of Diabetes Mellitus since 8

years taking irregular medication. He had surgical history of I & D of right Perianal abscess 8 months back .His vitals were within normal limit. Local examination revealed that 1st external opening at right perianal region.2nd external opening at base of scrotum, induration at 1 to 3 o clock position, Pus discharge present from boil site and ST at 6 o clock position.On proctoscopic examination, adequate dilation was present and dimple felt at 12 o clock position

After taking thoroughly history and routine laboratory investigations, he was diagnosed with Scotoanal fistula and admitted in IPD of shalyatantra department for surgical management.His vitals were within normal limits.

Laboratory Investigations:

Sr.No.	Investigation Name	Values
1	CBC	Hb- 11.8 gm/dl,RBC- 4.39 million,WBC-8950,PLT-298000
2	BSL	160 mg/dl
3	LFT	SGOT-31 IU/L ,SGPT-28 IU/L ,Sr. Alk Phosphatase-109 IU/L, Sr. Bilirubin =Total-0.69 mg/dl ,Direct-0.18 mg/dl,Indirect- 0.51 mg/dl
4	KFT	BUL-32.9 mg%,Creatinine-1.03, Sr.Sodium-128 mmol/L,Sr. Potassium -5.1 mmool/L
5	HbA1c	8.5 %
6	PTINR	1.08
7	HIV	Nonreactive
8	HBsAG	Nonreactive
9	Urine (R and M)	Sugar- +,Pus cells – 8 to 10/hpf
10	Chest Xray (PA view)	No active pleuroparenchymal lesion seen.
11	ECG	Normal
12	MRI Fistulogram	Small irregularly marginated area of abscess measuring 12^6^8 mm seen in right anterior perianal space at 11 0'clock postion with linear irregular hyperintense track extending from it anteriorly into right scrotal region and ultimately open onto posterior scrotal surface via one to two external openings. No obvious internal anal communications seen. Small irregularly marginated area of abscess measuring 22x10x26 mm seen in left anterior perianal space extending from 1 o'clock to 3 o' clock position.Thick linear irregular hyperintense track extending from this abscess anteriorly and ultimately opens into midline posterior scrotal skin surface.No internal anal communication seen.The left perianal abscess does not show any external perianal opening on overlying skin surface.

The patient underwent partial fistulectomy with Apamarga Ksharasutra application under spinal anaesthesia.Postoperative care included Jatyadi Taila dressings and internal Panchatikta Ghrita Guggulu. The wound was monitored weekly/biweekly using standardized criteria—Vrana Strava, Vrana Akrti, Vrana Varna, slough, pain, and odour. Healing Rate (cm³/week) and Unit Healing Time (days/cm) were calculated.

CLINICAL CRITERIAS FOR CASE STUDY:**Subjective criteria–**

1. *Vrana Vedana* / Pain
2. *Vrana Strava*/ Discharge

1. *Vrana Vedana* / Pain :

Pain was calculated on Visual analogue scale and scored as 1 to 10.

Explanation	Score	Grade
No pain	0	0
Mild Pain	1-3	1
Moderate Pain	4-6	2
Severe Pain	7-10	3

2. *Vrana Strava* (Discharge) :

Size of gauze piece – Double layered 10x10 cm.

Sign	Grade
No Discharge	0
Mild Discharge (If the wound wets 1 gauze piece in 24 hours)	1
Moderate discharge (If the wound wets 2 gauze pieces in 24 hours)	2
Severe Discharge (If the wound wets more than 2 gauze pieces in 24 hours)	3

Objective criteria:

- 1) *Vrana varna* (Granulation tissue formation)
- 2) *Vrana Akruti* (Surface area)
- 3) Slough
- 4) *Vrana Gandha* (Odour)
- 5) Duration of wound healing

1) Vrana Varna (Granulation tissue formation):

Granulation in percentage	Grade
Abundant (>75 % wound covered with granulation)	0
Moderate (51 % - 74 % wound covered with granulation)	1
Scanty (25%-50 % wound covered with granulation)	2
None (<25 % wound covered with granulation)	3

2) Vrana Akrti (Dimension):

Size of wound was taken by length and width of wound. This equation to calculate the area of irregular surface is -

$$\text{Volume} = L \times W \times D \text{ Cm}^2$$

Depth of wound: Depth of wound will be measured by Depth gauge (used in Orthopaedic surgery).

3) Slough

Slough	Grade
>76% wound covered with slough (ABUNDANT)	3
51%-75% wound covered with slough (MODERATE)	2
26%-50% wound covered with slough (SCANTY)	1
<25% wound covered with slough (NONE)	0

4) Gandha (Smell)

Smell	Grade
Foul smell intolerable	3
Tolerable but unpleasant smell	2
Bad smell	1
No smell	0

5) Duration of wound healing:

It will be measured as total time in days required for complete healing the wound.

Unit healing time =

Total no days for complete cutting of tract

Initial length of tract (thread)

OBSERVATIONS:

Wounds are assessed weekly for first four months and then biweekly for next months upto complete wound healing.

1) Subjective Criteria:

- a) *Vrana Vedana*
- b) *Vrana Gandha*

Weeks	<i>Vrana Vedana</i> (Pain)	<i>Vrana Gandha</i> (Odour)
Weekly Evaluation		
1 st week	3	2
2 nd week	3	2
3 rd week	3	2
4 th week	2	1
5 th week	2	1
6 th week	2	1
7 th week	2	1
8 th week	2	0
9 th week	2	0
10 th week	1	0
11 th week	1	0
12 th week	1	0
13 th week	1	0
Biweekly Evaluation of Grades		
14 th week	1	0
15 th week	1	0
16 th week	1	0
17 th week	1	0
18 th week	1	0
19 th week	0	0
20 th week	0	0
21 st week	0	0

2) Objective Criteria :

- a) *Vrana Gandha* (Smell)
- b) *Vrana Akruti* (Surface area)
- c) *Vrana Varna* (Granulation tissue formation)
- d) Slough

Weeks	Wound at base of Scrotum				Wound at right perianal region				Wound at left perianal region			
	Vrana Gandha	Vrana Akruti	Vrana Varna	Slough	Vrana Gandha	Vrana Akruti	Vrana Varna	Slough	Vrana Gandha	Vrana Akruti	Vrana Varna	Slough
Weekly												
1	2	70	3	3	2	120	3	3	2	210	3	3
2	2	70	3	3	2	120	3	3	2	210	3	3
3	2	60	3	3	2	120	3	3	2	210	3	3
4	2	60	3	3	2	120	3	3	2	120	3	3
5	2	40	3	3	2	96	3	3	2	175	3	3
6	2	40	2	2	2	72	3	3	2	150	3	3
7	2	30	2	2	2	60	2	3	2	120	2	3
8	2	24	2	2	2	60	2	3	2	120	2	3
9	2	16	2	2	2	60	2	2	2	100	2	2
10	2	12	2	1	2	36	2	2	2	60	2	2
11	1	8	2	1	1	24	2	2	1	60	2	2
12	1	6	2	1	1	24	2	2	1	48	2	2
13	1	6	1	1	1	24	1	1	1	36	1	1
Biweekly												
14	1	3	1	0	1	6	1	1	1	24	1	1
15	1	3	1	0	1	6	1	1	1	18	1	1
16	1	0	1	0	1	6	1	1	1	9	1	1
17	1	0	0	0	1	0	1	1	1	4	1	1
18	0	0	0	0	1	0	0	0	1	4	0	1
19	0	0	0	0	0	0	0	0	0	1	0	0
20	0	0	0	0	0	0	0	0	0	0	0	0
21	0	0	0	0	0	0	0	0	0	0	0	0

3) Ksharsutra:

Total three fistulous tracts present.

- First tract – In between wound at base of scrotum and wound at left perianal region
- Second tract – In between wound at right perianal region and anal region
- Third tract – In between wound at right perianal region and wound at base of scrotum

Weeks	1 st Tract	2 nd Tract	3 rd Tract
Weekly			
1 st week	7.5	6.0	5.0
2 nd week	7.0	6.0	5.0
3 rd week	6.5	5.8	4.5
4 th week	6.5	5.5	4.0
5 th week	6.0	5.2	3.5
6 th week	5.5	5.0	3.1
7 th week	5.0	4.5	3.0
8 th week	4.5	4.0	3.0
9 th week	4.0	3.8	2.8
10 th week	3.5	3.5	2.6
11 th week	3.0	3.0	2.0
12 th week	2.5	2.6	1.5
13 th week	2.5	2.2	1.0
Biweekly			
14 th week	2.5	2.0	0

15 th week	2.0	1.8	0
16 th week	1.5	1.5	0
17 th week	1.0	1.0	0
18 th week	0	0.5	0
19 th week	0	0	0
20 th week	0	0	0
21 th week	0	0	0

STATISTICAL ANALYSIS:

1) Subjective Parameters

Sr. No	Parameter	Week 1 Mean \pm SD	Week 21 Mean \pm SD	% Effect (Improvement)
1	Vrana Vedana (Pain)	3.0 \pm 0.0	0.0 \pm 0.0	100%
2	Vrana Gandha (Odour)	2.0 \pm 0.0	0.0 \pm 0.0	100%

At baseline (Week 1), the patient exhibited severe pain (*Vrana Vedana* score 3) and moderate foul odour (*Vrana Gandha* score 2). Serial weekly and biweekly evaluations revealed a progressive and sustained reduction in both parameters. Complete resolution of odour was observed by Week 8, while pain showed a gradual decline, achieving complete relief by Week 19. By Week 21, both parameters had reduced to 0 ± 0 , reflecting 100% clinical improvement. Statistical analysis using the Wilcoxon Signed-Rank Test demonstrated that the observed improvement was highly significant ($p < 0.001$), thereby confirming the therapeutic efficacy of the intervention.

2) Objective Parameters

Parameter	Wound Site	Week 1 Mean \pm SD	Week 21 Mean \pm SD	% Effect (Improvement)
Vrana Gandha (Odour)	Base of scrotum	2.0 \pm 0.0	0.0 \pm 0.0	100%
	Right perianal	2.0 \pm 0.0	0.0 \pm 0.0	100%
	Left perianal	2.0 \pm 0.0	0.0 \pm 0.0	100%
Vrana Akroti (Wound size, cm ²)	Base of scrotum	70.0 \pm 0.0	0.0 \pm 0.0	100%
	Right perianal	120.0 \pm 0.0	0.0 \pm 0.0	100%
	Left perianal	210.0 \pm 0.0	0.0 \pm 0.0	100%
Vrana Varna (Granulation)	All wounds	3.0 \pm 0.0	0.0 \pm 0.0	100%
Slough	All wounds	3.0 \pm 0.0	0.0 \pm 0.0	100%

At baseline (Week 1), all three wounds exhibited moderate foul odour (*Vrana Gandha* = 2), large wound size, poor granulation status (Grade 3), and heavy slough (Grade 3). Serial weekly and biweekly assessments demonstrated a progressive and consistent reduction in odour, wound size, and slough across all wound sites, accompanied by gradual improvement in granulation tissue formation. By Week 21, all wounds showed complete resolution of odour, wound size, and slough (0 ± 0), achieving 100% clinical improvement with healthy granulation and complete epithelialization. Statistical analysis using the Wilcoxon Signed-Rank Test confirmed that the observed improvements were highly significant ($p < 0.001$), substantiating the effectiveness of the therapeutic intervention.

3) Healing Rate (cm³/week):

$$\text{Healing Rate (cm}^3\text{/week)} = \frac{\text{Initial wound size} - \text{Final wound size}}{\text{Total duration of healing (Weeks)}}$$

Sr.No	Wound	Healing Rate (cm ³ /week)
1	Wound at Base of Scrotum	4.38 cm ³ /week
2	Wound at Right perianal region	7.06 cm ³ /week
3	Wound at Left perianal region	10.5 cm ³ /week

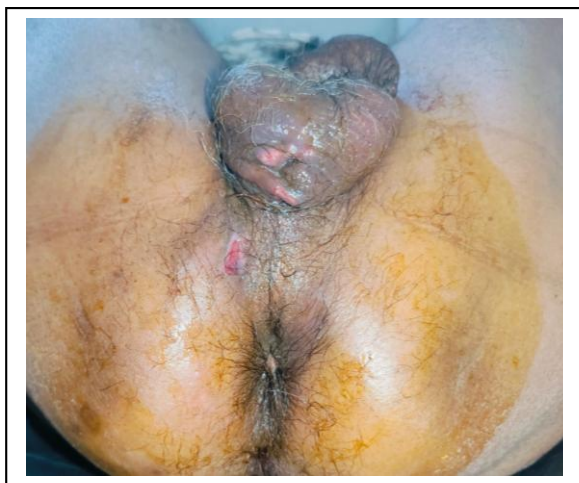The healing rates of the three wounds showed a progressive and site-dependent variation. The wound at the base of the scrotum demonstrated a healing rate of 4.38 cm³/week, indicating steady but comparatively slower wound contraction. The right perianal wound healed at a faster rate of 7.06 cm³/week, reflecting effective tissue response to *Ksharasutra* therapy. Notably, the left perianal wound, despite having the largest initial wound size, exhibited the highest healing rate of 10.5 cm³/week, suggesting enhanced wound contraction and granulation. These findings highlight the efficacy of Ayurvedic surgical intervention in promoting consistent and accelerated wound healing across anatomically complex regions.

4) Unit Healing Time (UHT):

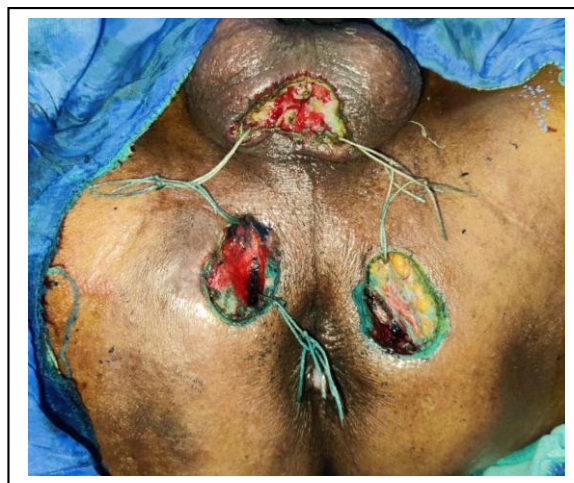$$\text{Unit Healing Time (UHT)} = \frac{\text{Total number of days for complete cutting of tract}}{\text{Initial length of tract}}$$

Sr.No	Tract	Unit Healing Time (days/cm)
1	1st Tract	16.8 days/cm
2	2nd Tract (Anal)	22.2 days/cm
3	3rd Tract	19.6 days/cm

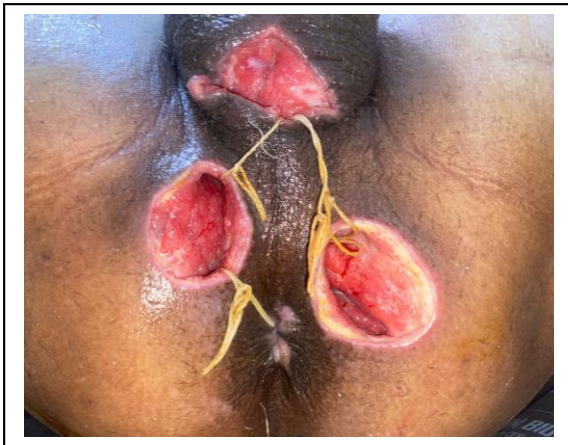The Unit Healing Time varied among the three fistulous tracts, with the 1st tract showing the fastest healing rate (16.8 days/cm), followed by the 3rd tract (19.6 days/cm), while the anal tract required a longer duration (22.2 days/cm) due to deeper location and sphincter involvement. These findings demonstrate effective and controlled cutting with simultaneous healing achieved through *Ksharasutra* therapy.



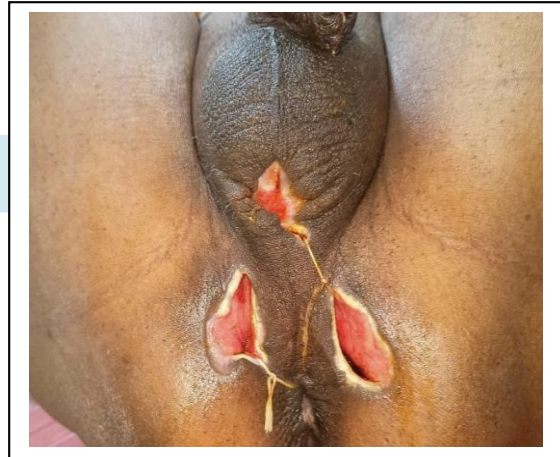
Before operation



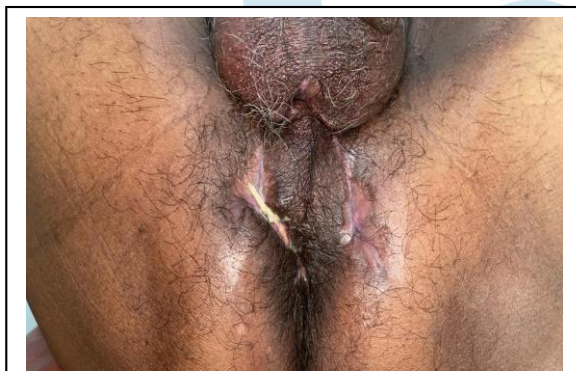At the time operation



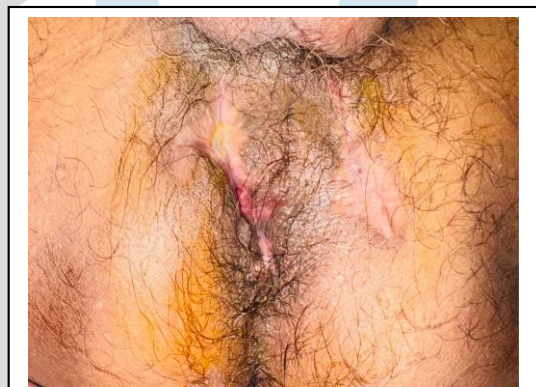8 th week



At 14 th week



18 th week



At 20 th week

RESULT:

The present case study demonstrates the successful management of a complex, recurrent scrotoanal fistula using Ayurvedic Shalyatantra interventions, particularly Apamarga Ksharasutra therapy combined with Jatyadi Taila and internal *Panchatikta Ghrita Guggulu*. Serial weekly and biweekly assessments showed complete resolution of pain, odour, discharge, wound size, and slough, with establishment of healthy granulation and complete epithelialization in all three wounds by Week 21.

The healing rates varied according to wound site, with the left perianal wound showing the fastest healing (10.5 cm³/week), followed by the right perianal (7.06 cm³/week) and scrotal wound (4.38 cm³/week), indicating effective wound contraction even in anatomically complex regions. Additionally, Unit Healing Time ranged from 16.8 to 22.2 days/cm,

DISCUSSION:

Bhagandara (fistula-in-ano) is a chronic, recurrent anorectal condition that poses significant therapeutic challenges, particularly in cases involving multiple tracts, scrotoanal extension, and prior surgical intervention. The present case involved a complex fistulous disease with three interconnected wounds and three fistulous tracts, necessitating a comprehensive and sustained treatment approach. The outcomes of this study were evaluated using systematic weekly and biweekly assessments encompassing both subjective and objective wound-healing parameters.

Subjective Parameters

Pain (*Vrana Vedana*) and foul odour (*Vrana Gandha*) are important indicators of inflammation, infection, and patient discomfort. At baseline, the patient experienced severe pain and moderate foul odour, reflecting active disease and ongoing infection. Serial evaluations demonstrated a gradual and sustained reduction in both parameters. Complete resolution of odour by Week 8 suggests effective control of infection and local wound contamination, while progressive reduction of pain culminating in complete relief by Week 19 indicates subsidence of inflammation and improved tissue healing. The statistically significant improvement ($p < 0.001$) confirms the clinical effectiveness of the intervention in alleviating patient-reported symptoms.

Objective Parameters

Objective assessment revealed marked improvement across all wounds with respect to odour, wound size (*Vrana Akriti*), granulation (*Vrana Varna*), and slough. Initially, all wounds exhibited large surface areas, poor granulation, and heavy slough, indicating unhealthy wound beds. Progressive weekly and biweekly evaluations demonstrated consistent reduction in wound size, elimination of slough, and improvement in granulation tissue formation. By Week 21, all three wounds achieved complete epithelialization with 100% reduction in odour, wound size, and slough, signifying complete wound healing. Statistical analysis using the Wilcoxon Signed-Rank Test showed highly significant improvement ($p < 0.001$), validating the reliability of the observed outcomes.

Healing Rate Analysis

Healing rate analysis further highlighted the effectiveness of the intervention across different anatomical sites. Although the wound at the base of the scrotum demonstrated a comparatively slower healing rate (4.38 cm³/week), steady wound contraction was evident. The right perianal wound healed at a faster rate (7.06 cm³/week), while the left perianal wound—despite having the largest initial wound size—exhibited the highest healing rate (10.5 cm³/week). This site-dependent variation suggests that larger wounds may undergo more rapid contraction once adequate drainage, debridement, and granulation are established. These findings underscore the ability of Ayurvedic surgical intervention to promote consistent and accelerated wound healing even in anatomically complex regions.

Ksharasutra and Unit Healing Time

The presence of three fistulous tracts with varying anatomical courses allowed for detailed evaluation of Unit Healing Time (UHT). The first tract demonstrated the shortest UHT (16.8 days/cm), followed by the third tract (19.6 days/cm), while the anal tract required a longer duration (22.2 days/cm), likely due to deeper location, sphincter involvement, and continuous mechanical stress. Despite these variations, all tracts healed successfully through controlled cutting and simultaneous healing, reflecting the precision and effectiveness of Ksharasutra therapy.

CONCLUSION:

The present case study demonstrates the successful management of a complex, recurrent scrotoanal fistula using Ayurvedic Shalyatantra intervention, particularly Apamarga Ksharasutra therapy supported by Jatyadi Taila and internal Panchatikta Ghrita Guggulu. Systematic weekly and biweekly assessments showed complete resolution of pain, odour, wound size, slough, and discharge, with establishment of healthy granulation and complete epithelialization in all three wounds by the end of the follow-up period.

The observed site-dependent healing rates and favorable Unit Healing Time values confirmed effective wound contraction and controlled cutting with simultaneous healing of all fistulous tracts, even in anatomically complex regions. The statistically significant improvements further validate the therapeutic efficacy of the intervention.

Overall, this case highlights that Ksharasutra therapy is a safe, minimally invasive, cost-effective, and recurrence-preventive modality for the management of complex fistula-in-ano, particularly in recurrent and antibiotic-resistant cases.

The successful outcome without recurrence highlights the potential of Ayurvedic Shalyatantra interventions as a viable and sustainable approach for complex fistula in ano.

The findings reinforce the role of Ayurveda as an emerging aid for global healthcare, offering sustainable and patient-centered solutions for challenging surgical conditions.

REFERENCES:

1. Sushruta Samhita, Nidana Sthana 1/3; edited by Acharya YT; Chaukhamba Sanskrit Sansthan, Varanasi; 2018: p.260.
2. Sushruta Samhita, Nidana Sthana 4/4; edited by Acharya YT; Chaukhamba Sanskrit Sansthan, Varanasi; 2018: p.272.
3. Vagbhata. Ashtanga Hridaya, Nidana Sthana 9/5; edited by Gupta A; Chaukhamba Krishnadas Academy, Varanasi; 2019: p.498.
4. Sushruta. Sushruta Samhita, Nidana Sthana 4/7–11; edited by Acharya YT; Chaukhamba Sanskrit Sansthan, Varanasi; 2018: p.273–274.
5. Sushruta. Sushruta Samhita, Chikitsa Sthana 8/17; edited by Acharya YT; Chaukhamba Sanskrit Sansthan, Varanasi; 2018: p.431.
6. Vagbhata. Ashtanga Hridaya, Sutra Sthana 30/28; edited by Gupta A; Chaukhamba Krishnadas Academy, Varanasi; 2019: p.214.
7. Charaka. Charaka Samhita, Chikitsa Sthana 12/96–98; edited by Sharma PV; Chaukhamba Bharati Academy, Varanasi; 2017: p.456–457.
8. Williams NS, O'Connell PR. Fistula in Ano. In: Williams NS, Bulstrode C, O'Connell PR, editors. Bailey & Love's Short Practice of Surgery, 27th ed. Boca Raton: CRC Press; 2018. Chapter 74, p. 1356–1360.
9. Steele SR, Kumar R. Etiology and Pathophysiology of Anal Fistulas. In: Beck DE, Roberts PL, et al., editors. ASCRS Textbook of Colon and Rectal Surgery, 4th ed. New York: Springer; 2022. Chapter 16, p. 331–333.
10. Parks AG, Gordon PH, Hardcastle JD. A classification of fistula-in-ano. In: Gordon PH, Nivatvongs S, editors. Principles and Practice of Surgery for the Colon, Rectum, and Anus, 3rd ed. St. Louis: Quality Medical Publishing; 2007. Chapter 14, p. 235–236.
11. Townsend CM, Beauchamp RD, Evers BM. Anal Fistula: Clinical Features. In: Sabiston Textbook of Surgery, 21st ed. Philadelphia: Elsevier; 2022. Chapter 52, p. 1420–1422.
12. Rivadeneira DE, Ruffo B. Complex and Recurrent Fistula-in-Ano. In: Feingold DL, Steele SR, editors. The ASCRS Manual of Colon and Rectal Surgery, 2nd ed. Springer; 2019. Chapter 13, p. 201–205.
13. Halligan S, Stoker J. Imaging of Fistula-in-Ano. In: Gore RM, Levine MS, editors. Textbook of Gastrointestinal Radiology, 5th ed. Philadelphia: Elsevier; 2021. Chapter 48, p. 1023–1026.
14. Steele SR, Hull TL. Surgical Management of Anal Fistula. In: Wolff BG, Fleshman JW, Beck DE, et al. The ASCRS Textbook of Colon and Rectal Surgery, 4th ed. Springer; 2022. Chapter 17, p. 339–348.
15. Schwartz SI, Brunickardi FC. Complications and Recurrence in Fistula-in-Ano. In: Schwartz's Principles of Surgery, 11th ed. New York: McGraw-Hill; 2019. Chapter 29, p. 1256–1258.
16. Williams NS, O'Connell PR. Complex Anal Fistula. In: Williams NS, Bulstrode C, O'Connell PR, editors. Bailey & Love's Short Practice of Surgery, 27th ed. CRC Press; 2018. Chapter 74, p. 1356–1358.

17. Steele SR, Kumar R. Classification and Evaluation of Fistula-in-Ano. In: Beck DE, Roberts PL, editors. ASCRS Textbook of Colon and Rectal Surgery, 4th ed. Springer; 2022. Chapter 16, p. 331–335.
18. Townsend CM, Beauchamp RD, Evers BM. Chronic Perianal Sepsis and Fistula. In: Sabiston Textbook of Surgery, 21st ed. Elsevier; 2022. Chapter 52, p. 1420–1424.
19. Hull TL, Steele SR. Recurrence after Anal Fistula Surgery. In: Wolff BG, Fleshman JW, editors. The ASCRS Textbook of Colon and Rectal Surgery, 4th ed. Springer; 2022. Chapter 17, p. 339–344.
Parks AG, Gordon PH. Epidemiology of Anal Fistula. In: Gordon PH, Nivatvongs S, editors. Principles and Practice of Surgery for the Colon, Rectum, and Anus, 3rd ed. Quality Medical Publishing; 2007. Chapter 14, p. 230–232.
20. Schwartz SI, Brunickardi FC. Factors Contributing to Recurrence in Fistula-in-Ano. In: Schwartz's Principles of Surgery, 11th ed. McGraw-Hill; 2019. Chapter 29, p. 1256–1258.
21. Deshpande PJ, Sharma KR. Clinical evaluation of Ksharasutra therapy in fistula-in-ano. *Indian Journal of Surgery*. 1977;39(5):251–256.
22. Narayana A, Shriram V. Standardization and clinical efficacy of Ksharasutra in fistula-in-ano. In: CCRAS Publication, Ministry of AYUSH; New Delhi; 2015. p. 45–52.
23. Gupta SK, Bhuyan C, Sikarwar MS. Role of Ksharasutra in complex and high anal fistulas: A clinical review. *Ayu*. 2011;32(3):360–365.
24. Sahoo AK, Kumar S. Management of recurrent fistula-in-ano with Ksharasutra: A prospective study. *Journal of Research in Ayurveda and Siddha*. 2004;25(1):12–18.
25. Lunniss PJ, Phillips RKS. Surgical management challenges in complex anal fistula. *British Journal of Surgery*. 1994;81(9):1382–1385.
26. World Health Organization. Global report on antimicrobial resistance. WHO Press; Geneva; 2014. p. 1–15.

IJRTI

MRI FISTULOGRAM**PROTOCOL :**

Multiplanar MRI fistulogram was performed using T1 weighted spin echo, T2 weighted fast spin echo and fast STIR sequences.

OBSERVATIONS :

Small irregularly marginated area of sepsis / abscess measuring 12 x 6 x 8 mm seen in right anterior perianal space at 11 O' clock position with thick linear irregular hyperintense track extending from it anteriorly into right scrotal region and ultimately open onto posterior scrotal surface via one to two external openings. No obvious internal anal communication seen. The right perianal abscess shows external opening on overlying perianal skin surface.

Small irregularly marginated area of sepsis / abscess measuring 22 x 10 x 26 mm seen in left anterior perianal space extending from 1 O' clock to 3 O' clock position. Thick linear irregular hyperintense track extending from this abscess anteriorly and ultimately opens onto midline posterior scrotal skin surface. No internal anal communication seen. The left perianal abscess does not show any external perianal opening on overlying skin surface.

Urinary bladder is normal.

Bilateral ischiorectal fossae are normal.

Visualized sacrum and lower vertebra appears normal.

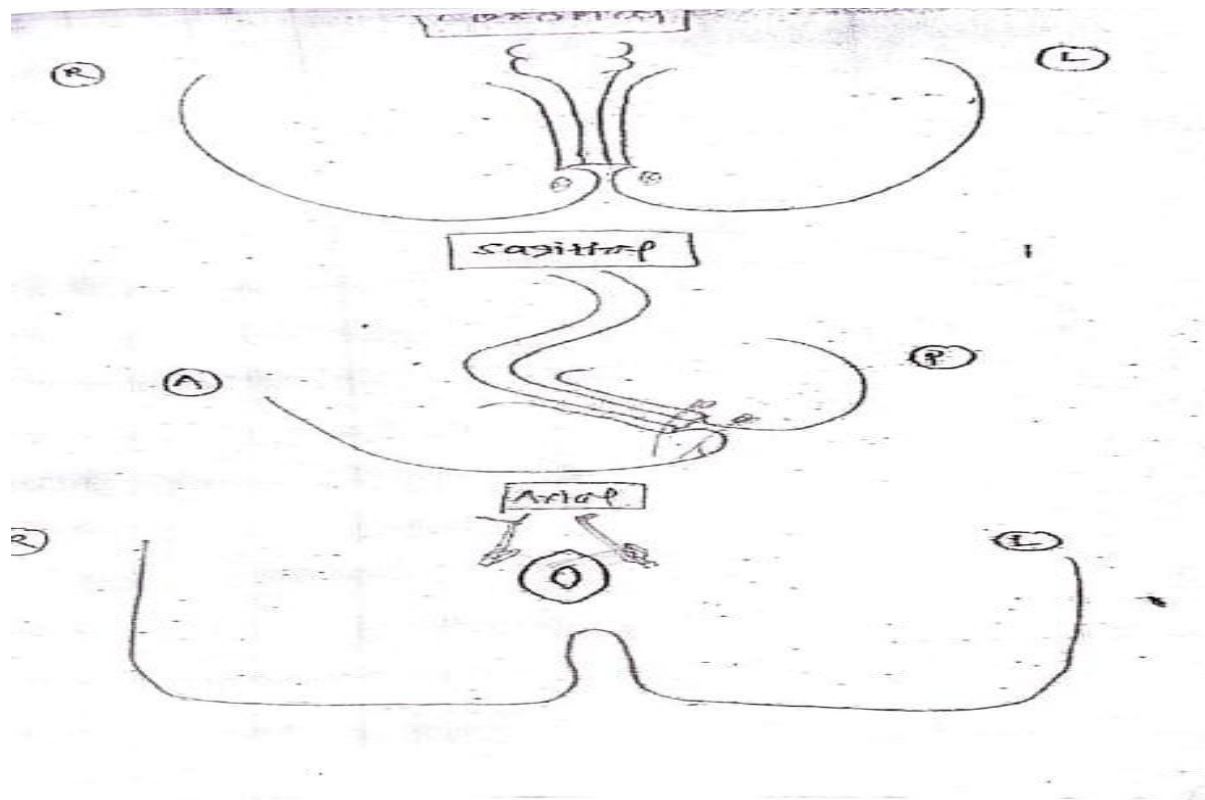
Visualized pelvic soft tissue appears normal.

Visualised pelvic bones are normal.

Cont.....

IMPRESSION :

- *Small irregularly marginated area of sepsis / abscess measuring 12 x 6 x 8 mm seen in right anterior perianal space at 11 O' clock position with thick linear irregular hyperintense track extending from it anteriorly into right scrotal region and ultimately open onto posterior scrotal surface via one to two external openings. No obvious internal anal communication seen. The right perianal abscess shows external opening on overlying perianal skin surface.*
- *Small irregularly marginated area of sepsis / abscess measuring 22 x 10 x 26 mm seen in left anterior perianal space extending from 1 O' clock to 3 O' clock position. Thick linear irregular hyperintense track extending from this abscess anteriorly and ultimately opens onto midline posterior scrotal skin surface. No internal anal communication seen. The left perianal abscess does not show any external perianal opening on overlying skin surface*



Others (Culture/ Sensitivity C/S Test

Investigation	Result
SPECIMEN	PUS
MEDIA	MacConkey Agar, Blood Agar, Hi-Chrome Agar, Mueller-Hinton Agar
ORGANISM ISOLATED	PSEUDOMONAS AERUGINOSA
COLONY COUNT	MODERATE
AMIKACIN (AK)	RESISTANT
IMEPENEM (IMP)	INTERMEDIATE
MEROPENEM (MRP)	INTERMEDIATE
GENTAMICIN (G)	RESISTANT
CEFTAZIDIME (CA)	RESISTANT
CIPROFLOXACIN (CF)	RESISTANT
PIPERACILLIN-TAZOBACTUM (PTZ)	RESISTANT
CEFOPERAZONE-SULBACTAM (C/S)	RESISTANT
NETILMICIN (NT)	RESISTANT
CEFTRIAXONE (CI)	RESISTANT
OFLOXACIN (OF)	RESISTANT
COLISTIN (CL)	MIC: 0.25ug/ml: SENSITIVE
CEFUROXIME (CU)	RESISTANT
LEVOFLOXACIN (LE)	RESISTANT

----- END OF REPORT -----