

# Evaluation of anti-ulcer activity of *Atlantia Monophylla*

<sup>1</sup>Eppaturi Prasanthi, <sup>2</sup>C. Pavan kalyan, <sup>3</sup>K. Somasekhar reddy

<sup>1</sup>M.Pharmacy student, <sup>2</sup>M.Pharmacy student, <sup>3</sup>Head of the Department, M.Pharm., PhD.

<sup>1</sup>Department of Pharmacology,

<sup>1</sup>Raghavendra Institute of Pharmaceutical Education and Research (RIPER), Ananthapur, India.

**Abstract:** *Osyris quadripartita* (OQ) Salzm. ex Decne. has been used to treat peptic ulcer disease in Ethiopian folk medicine, but its efficacy has not been validated. The present study was therefore carried out to evaluate the anti-ulcer activity of 80% methanol leaf extract of OQ in rats. The effect of OQ extract on gastric ulcer in rats in pylorus ligation-induced and ethanol-induced models was studied using single dosing (100, 200, 400 mg/kg) and repeated dosing (200 mg/kg for 10 and 20 days) approaches. Ranitidine (50 mg/kg) and sucralfate (100 mg/kg) were used as the standard drugs. Depending on the model, outcome measures were volume and pH of gastric fluid, total acidity, ulcer score, percent inhibition of ulcer score, ulcer index as well as percent inhibition of ulcer index. Data were analyzed using one-way analysis of variance followed by Tukey's post hoc test, and  $P < 0.05$  was considered as statistically significant. OQ significantly ( $P < 0.001$ ) reduced gastric ulcer index by 55.82% and 62.11%, respectively, in pylorus ligation-induced and ethanol-induced ulcer models at the 400 mg/kg dose, which is comparable to the standard drugs. Ten and 20 days pre-treatment with OQ200 exhibited significant ( $P < 0.001$ ) ulcer inhibition by 66.48% and 68.36% (pylorus ligation-induced model) as well as 71.48% and 85.35% (ethanol-induced model), respectively.

**Keywords:** Liver, xenobiotics, paracetamol, SGOT, SGPT.

## I. INTRODUCTION

Liver is the largest organ in the body and vital for survival. It performs wide range of functions like synthesis of proteins, storage of vital compounds and metabolism of xenobiotics and endogenous substances. Because of its multidimensional functions and exposure to wide range of chemicals liver is more prone to damage. However, liver has a large capacity for handling toxicants and a high potential for regeneration. In most of the cases it only produces symptoms after extensive damage. The xenobiotics like antitubercular drugs, chronic alcoholic consumption, paracetamol overdosing and organophosphorus compounds damages hepatic cells. The drug induced hepatotoxicity is a major health problem.

*A. grossus* a species of family- Cyperaceae and is a perennial herb with long rhizomes that end in small tubers that is found throughout India and neighboring Asian countries and is popularly known as 'Kasheruka' in Ayurveda. It has been used in Ayurvedic medicine to treat liver and stomach problems. However, there is no experimental evidence to support its hepatoprotective effect and hence, the current research was designed to assess the hepatoprotective efficacy of *A. grossus* extract in two different experimental models.

Paracetamol is most commonly used antipyretic agent which is very safe in therapeutic doses but in toxic doses paracetamol can produce serious fatal hepatic necrosis in animals. Present study we have opted paracetamol induced hepatotoxicity as one of the experimental models. Earlier studies established that paracetamol at 3g/kg dose can readily cause severe hepatic injury in animals. The extent of liver damage can be assessed by measuring biochemical parameters such as SGOT, SGPT, alkaline phosphatase, albumin, total protein, direct bilirubin, total bilirubin levels and levels of antioxidants in liver homogenate and histopathology studies of liver tissues. Paracetamol causes hepatotoxicity mainly by undergoing metabolic process to release N-Acetyl-p-benzoquinone-imine (NAPQI) an active metabolite.

## II. AIM AND OBJECTIVES:

### Aim:

To determine the hepatoprotective activity of ethanolic extract of plant *A. grossus* tuber in Wistar albino rats.

### Objective:

1. Phytochemical, microscopic investigations and HPTLC, HPLC, GCMS profiling of plant *A. grossus*.
2. To study the acute oral toxicity and determination of LD50 of ethanolic extract of *A. grossus* in Wistar albino rats.
3. Evaluation of the protective effects of ethanolic extract of *A. grossus* against paracetamol induced hepatotoxicity in Wistar albino rats by estimating liver enzymes, lipid profile, antioxidant level and histopathological changes of liver.
4. Evaluation of protective effects of ethanolic extract of *A. grossus* against ethyl alcohol induced hepatotoxicity in Wistar albino rats by estimating liver enzymes, lipid profile, antioxidant level and histopathological changes of liver.

## Approach

Institutional animal ethics committee (IAEC) permission was obtained from K.S.Hegde Medical Academy (KSHEMA) (Reg No: 115/1999/CPCSEA) before starting the animal experiment. The study was conducted from January 2015 to February 2019.

### III. LITERATURE REVIEW:

Largest organ and largest gland in the human body is liver. It has tremendous power to regenerate. It carries out wide range of essential functions in body such as metabolism of both endogenous and exogenous chemicals and detoxification of metabolites. It functions as a store house for vitamins A, D, E, K, B12, sugar, iron and copper. It is responsible for synthesis of cholesterol, bile acids, albumin, clotting factors and angiotensinogen. The bile helps the break down and absorption of fats, cholesterol, bilirubin, and electrolyte and fat-soluble vitamins from the intestine. Hepatic systems consisting of high numbers of kupffer cells that are involved in immune activity that destroys disease causing agents which enter the liver through the gut [1, 2]. The liver is important in maintaining metabolic homeostasis. It maintains a steady supply of substrate that can be oxidised to generate energy. It has the ability to store substrates as a reservoir during feeding and to degrade these stocks during fasting. Glucose, fatty acids, and ketone bodies are essential biochemical fuels in the human body. Its primary energy sources are glycogen in the liver, triglycerides in adipose tissue, and muscle proteins.

#### Anatomy of liver:

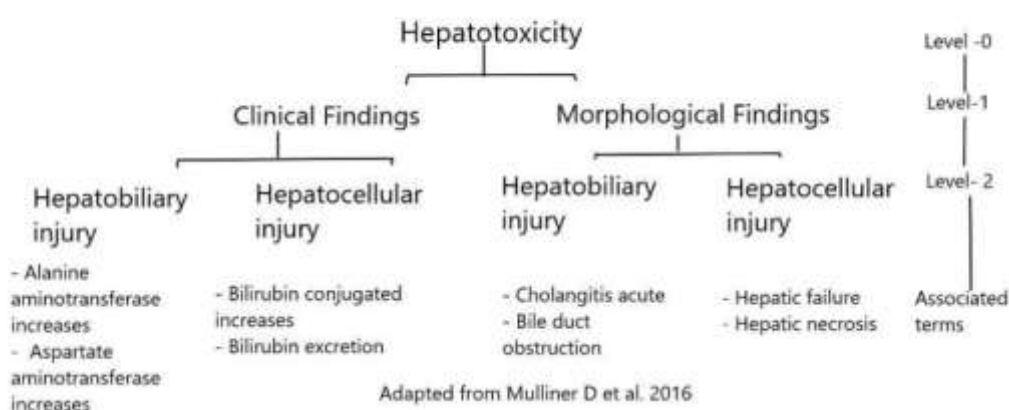
The size of the liver varies with age, gender, and body size. The liver is described as having superior, anterior, right, posterior and inferior surfaces. The superior surface is located directly under the diaphragm and is isolated from the peritoneum except for a small triangular region where two layers of the falciform ligament diverge. Except at the attachment of falciform ligament it is covered by peritoneum. The right surface lies adjacent to the right dome of the diaphragm, which separates it from right lung and pleura and seventh to eleventh ribs right surface and covered by peritoneum. The posterior surface of the liver is convex wide on the right and narrow on the left. Much of the posterior surface is attached to diaphragm by loose connective tissue and forms triangular bare area.

#### Functions of liver:

Liver plays an important role in the process of digestion and metabolism of food and wide range of chemicals. Hepatocytes does several vital roles in maintaining homeostasis in body. The fact that mitochondria are maximally present in the liver emphasizes that liver is involved in many biochemical functions.

### Hepatotoxicity

Hepatotoxicity is injury to the liver that is associated with impaired liver function caused by exposure to a drug or another non-infectious agent. Liver damage may be caused by several factors such as xenobiotics, alcohol consumption, malnutrition, hepatitis, anaemia and overdoses of some medications. These factors can react with the basic cellular components and later induce almost all types of liver lesions. Hepatotoxicity is associated with cellular necrosis, increase in tissue lipid peroxidation and depletion in the tissue GSH levels. In addition, serum levels of many biochemical markers like ALP, SGOT, SGPT, Triglycerides, cholesterol, bilirubin, are elevated. Toxins are the basic etiopathogenetic agents of acute liver failure in Western countries [21]. Several chemicals have been known to induce liver toxicity.



### Alcoholic liver disease (ALD)

Chronic alcohol consumption leads to alcoholic liver disease (ALD) commonly seen around the world. The primary risk factors for ALD risk include drinking patterns, sex, obesity, co-existing viral infection, and genetic factors. ALD includes a broad spectrum of disorders, such as simple steatosis, cirrhosis, acute alcoholic hepatitis (AH) with or without cirrhosis, and hepatocellular carcinoma (HCC) as a complication of cirrhosis.

### Experimental models of hepatotoxicity

Animal model provides the information about drug or describe their potency in prevention and cure of various hepatic diseases. Various chemical agents normally used for inducing animal hepatotoxicity include carbon tetrachloride (CCl<sub>4</sub>), paracetamol, acrylamide, adriamycin, alcohol, antitubercular drugs etc. Two major types are in vivo and in vitro, in vivo models known concentration of hepatotoxin is administered for a defined period of time and route to induce liver damage. Here test substance is administered either before or after the toxin treatment. In in-vitro models hepatic cell lines are used. Hepatic cell lines are treated with hepatotoxin and the effect of the test drugs on the same is evaluated.

#### **Hepatoprotective herbal medicines:**

Therapeutic usage of herbal medicines in liver disorders gaining popularity around the globe. Efforts are going on to validate the therapeutic benefits of phytomedicines in liver disease through scientific tools like preclinical and clinical trials. It has been reported that many herbs possess potent hepatoprotective activities and can fulfill the therapeutic gap existing in the treatment of liver diseases. Herbs are considered to be the great reservoirs of therapeutically active and structurally diverse lead molecules. Thus, validating such molecules from herbs will add great value for natural products mentioned in the complimentary system of medicines. It may also reduce the huge investments, manpower and time from conventional development of pharmaceutical products.

**Botanical description about plant *Scirpus grossus* L.F. or its other synonyms is *Actinoscirpus grossus* (L. f.) Goetgh. & D. A. Simpson**

**Figure -1: *Actinoscirpus grossus* (L. f.) Goetgh. & D. A. Simpson plant:**



**Figure 2 -Dried form of *Actinoscirpus grossus* (L. f.) Goetgh. & D. A. Simpson plant and tuber**



The plant grows as a perennial with long stolons or rhizomes that end in little tubers. The stem is three-angled and concave ends, up to 200 cm long and 10 mm thick, septate, smooth or somewhat scabrid at the tip. The leaves are 50–80 cm long, up to 2 cm thick, keeled below, and have scabrid, bristly edges and a pointed tip. Sheaths are broad, spongy, and straw-colored, with prominent transverse veinlets. *A.grossus* belongs to family cyperaceae. The inflorescence is a terminal, irregular, multi-branched umbel. The branches are all at the extremities of the primary branches, and it is around 5–17 cm long and narrowly pointed. Inflorescence consists of two to three leafy bracts and measures about 15–70 cm long. Spikelets are solitary, sessile or peduncled, narrowly ovoid in shape and 3–10 mm long and 2–4 mm wide, and densely many-flowered.

#### **Need of the study**

Despite the tremendous advances made in allopathic no effective hepatoprotective and curative medicines are available. Pharmacotherapeutic options available for liver diseases are very limited and there is a great demand for the development of new effective drugs in this field. *A. grossus* tubers are popularly used for chronic illness in indigenous practice in India.

#### IV. MATERIALS AND METHODS:

##### 4.1 Test drug– Ethanollic extract of *A. grossus* tuber (EAGT)

##### 4.1.2 Reference standard hepatoprotective drugs:

- Silymarin** tablet was used in the present study (Silybon -140 mg Batch no:SIBD0047, Mfd-Apr 2013, Exp -Mar 2016, Manufactured by micro lab limited,HB-211,Village Katha P.O.Boddi, Tehsil Nalagarhdist , Solan173205(H.P)
- Liv 52** syrup formulation was used in the study (Liv 52 DS SYRUP 200 ml Batch no-20500638, Mfd-May2015, Exp-May 2018, Manufactured by: the Himalayan Drug company at: (20):182, Village Gurumajra, Kishanpur, Solan, Himachal Pradesh.

##### 4.1.2 Toxicants

- Paracetamol** tablets were used to induce hepatotoxicity in the present study. (Brand name-PYREMOL-500mg), Batch no-BI5022021, MFG - 12/2015, EXP-11/2018, Manufactured in Shiva Biogenetic pharmaceuticals Pvt Ltd,vill.Manpura , Baddidist :Solan(H.P) -174101.
- Ethyl alcohol**- Ethanol 99% purity grade was used for hepatotoxicity in the present study (Batch number-XK-13-201-00185, Manufactured in Changshuyanguanchemical, China).

#### 4.2 Methodology

##### 4.2.1 Collection of plant materials and extract preparation:

*A.grossus* plant tubers were procured from the herbal garden at Karnal, Haryana during the month June 2014 and was authenticated at Vaidya Hukam Chand Arogyadham Gharaunda, Haryana, India. Sample was stored in Pharmacognosy Laboratory of the Sri Dharmasthal Manjunatheshwara Centre for Research in Ayurveda & Allied Sciences, Udupi for future reference with voucher specimen (No. 495/14101822). Using a pulverizer the tuber was shade dried and powdered at SDM Pharmacy in Udupi. The ethanollic extract was produced by soaking 430g of powdered *A. grossus* tuber in 3.5 litres of ethanol for 24 hours, then filtering and concentrating by evaporating on a water bath until free of water. It was thoroughly dried using a vacuum. The proportion of dried extract with contrast to the sample taken was noted.

##### 4.2.2 Microscopy

Sample was preserved in fixative solution. The fixative used was FAA (Formalin-5ml + Acetic acid-5ml + 70% Ethyl alcohol-90ml). The materials were left in FAA for quite 48 hours. The preserved specimens were cut into thin transverse section employing a sharp blade and the sections were stained with saffranine. The slides were also stained with iodine in potassium iodide for detection of starch. Later transverse sections were photographed using Zeiss AXIO trinocular microscope attached with Zeiss Axio Cam camera under bright field light. Magnifications of the figures are indicated by the scale-bars [155].

#### V.RESULTS:

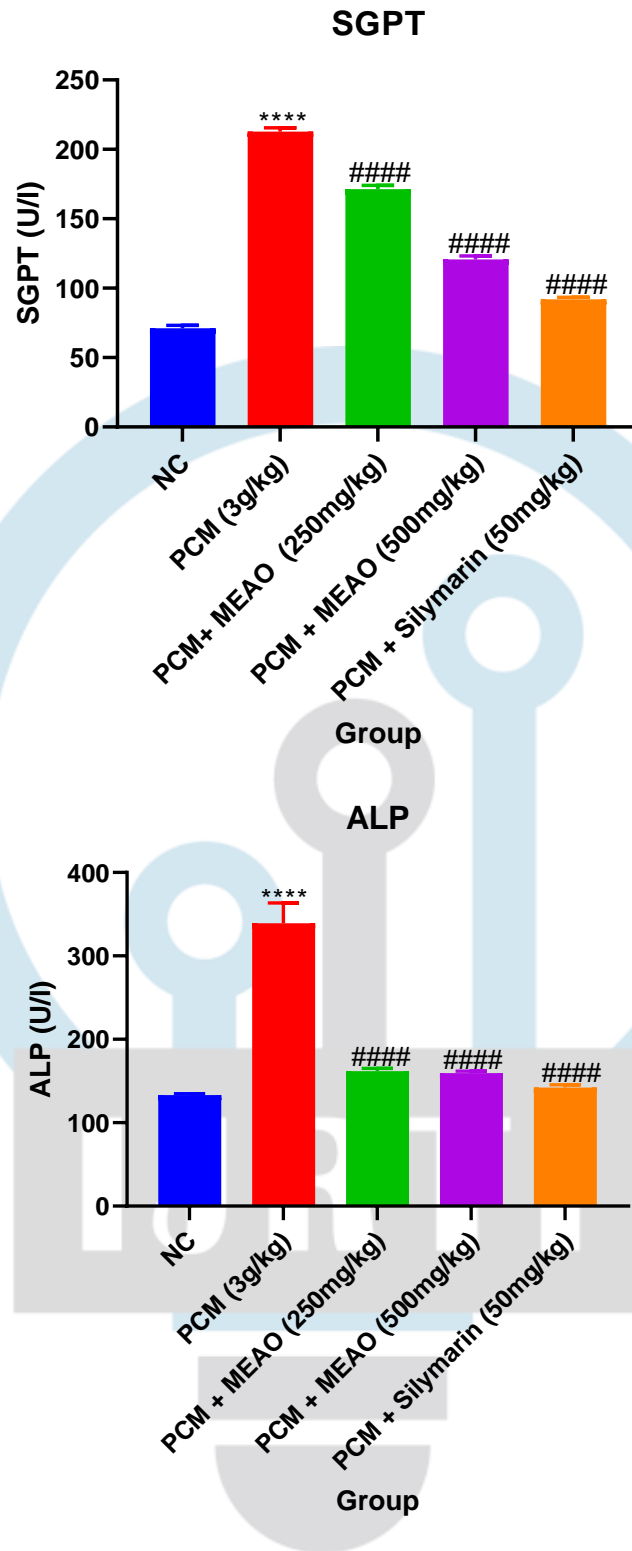
**Effect of methanolic extract of *Albizia odoratissima* on liver marker enzymes**

Group	SGPT (U/l)	SGOT(U/l)	ALP(U/l)	TP(U/l)
NC	71.1±2.03	83.8±1.23	133.0±1.66	7.6±0.20
PCM	212.8±2.84****	286.1±5.65****	339.1±24.23****	3.3±0.18****
PCM + MEAO (250mg/kg, P.O)	171.4±2.72####	182.4±2.33####	161.9±3.10####	6.6±0.14####
PCM (500mg/kg, P.O)	120.8±2.38####	136.0±1.72####	159.4±2.32####	6.6±0.14####
PCM + Silymarin (50mg/kg, P.O)	91.8±1.52####	96.8±1.17####	142.1±3.33####	7.4±0.24####

All values are expressed mean±SEM (N=6). NC indicates normal control group; PCM paracetamol induced hepatotoxic group, Paracetamol induced hepatotoxic group rats treated with Methanolic extract of *Albizia Odoratissima* at dose 250mg/kg/ P.O (PCM + MEAO 250mg/kg, P.O), Paracetamol induced hepatotoxic group rats treated with Methanolic extract of *Albizia Odoratissima* at dose 500mg/kg/ P.O (PCM + MEAO 500mg/kg, P.O). Paracetamol induced hepatotoxic group rats treated with Silymarin at dose 50mg/kg P.O (PCM + Silymarin 50mg/kg P. O).

\*\*\*\*P<0.0001 compared with normal control

####P<0.0001 compared with Paracetamol group



All values are expressed mean±SEM (N=6). NC indicates normal control group; PCM paracetamol induced hepatotoxic group, Paracetamol induced hepatotoxic group rats treated with Methanolic extract of Albizia Odoratissima at dose 250mg/kg/ P.O (PCM + MEAO 250mg/kg, P.O), Paracetamol induced hepatotoxic group rats treated with Methanolic extract of Albizia Odoratissima at dose 500mg/kg/ P.O (PCM + MEAO 500mg/kg, P.O). Paracetamol induced hepatotoxic group rats treated with Silymarin at dose 50mg/kg P.O (PCM + Silymarin 50mg/kg P. O).

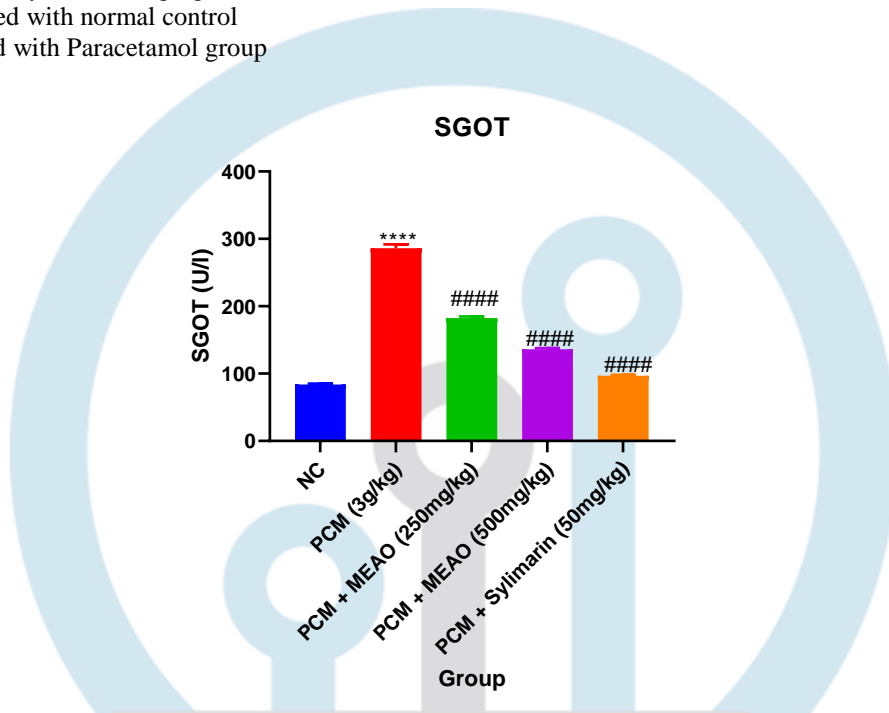
\*\*\*\*P<0.0001 compared with normal control

####P<0.0001 compared with Paracetamol group

All values are expressed mean±SEM (N=6). NC indicates normal control group; PCM paracetamol induced hepatotoxic group, Paracetamol induced hepatotoxic group rats treated with Methanolic extract of Albizia Odoratissima at dose 250mg/kg/ P.O (PCM + MEAO 250mg/kg, P.O), Paracetamol induced hepatotoxic group rats treated with Methanolic extract of Albizia Odoratissima at dose 500mg/kg/ P.O (PCM + MEAO 500mg/kg, P.O). Paracetamol induced hepatotoxic group rats treated with Silymarin at dose 50mg/kg P.O (PCM + Silymarin 50mg/kg P. O).

\*\*\*\*P<0.0001 compared with normal control

####P<0.0001 compared with Paracetamol group



All values are expressed mean±SEM (N=6). NC indicates normal control group; PCM paracetamol induced hepatotoxic group, Paracetamol induced hepatotoxic group rats treated with Methanolic extract of Albizia Odoratissima at dose 250mg/kg/ P.O (PCM + MEAO 250mg/kg, P.O), Paracetamol induced hepatotoxic group rats treated with Methanolic extract of Albizia Odoratissima at dose 500mg/kg/ P.O (PCM + MEAO 500mg/kg, P.O). Paracetamol induced hepatotoxic group rats treated with Silymarin at dose 50mg/kg P.O (PCM + Silymarin 50mg/kg P. O). \*\*\*\*P<0.0001 compared with normal control, ####P<0.0001 compared with Paracetamol group.

