

Herpes simplex: An overview

¹Dr. Puja Bansal, ²Sanjana Thakur, ³Ankush Kalra, ⁴Rodricks

¹Professor, ^{2,3,4}Students
School of Dental Science
Sharda University

Introduction-

Herpes simplex viruses are ubiquitous, host-adapted pathogens that cause a wide variety of disease states. Herpes simplex, infection of either the skin or the genitalia caused by either of two strains of herpes simplex virus. The herpes simplex virus is categorized into 2 types: herpes simplex virus type 1 (HSV-1) and herpes simplex virus type 2 (HSV-2).

HSV-1 is mainly transmitted by oral-to-oral contact to cause oral herpes (which can include symptoms known as “cold sores”), but can also cause genital herpes. HSV-2 is a sexually transmitted infection that causes genital herpes. The spectrum of disease caused by HSV includes primary and recurrent infections of mucous membranes (e.g., gingivostomatitis, herpes labialis, and genital HSV infections), keratoconjunctivitis, neonatal HSV infection, visceral HSV infections in immunocompromised hosts, HSV encephalitis, Kaposi’s varicella-like eruption, and an association with erythema multiforme. {1}

HSV1-

Herpes simplex virus type 1 (HSV-1) is a member of the Alphaherpesviridae subfamily. Its structure is composed of linear dsDNA, an icosahedral capsid that is 100 to 110 nm in diameter, with a spiky envelope. In general, the pathogenesis of HSV-1 infection follows a cycle of primary infection of epithelial cells, latency primarily in neurons, and reactivation {2}. HSV-1 is responsible for establishing primary and recurrent vesicular eruptions, primarily in the orolabial and genital mucosa.

Etiology-

Risk factors for HSV-1 infection differ depending on the type of HSV-1 infection. In the case of orolabial herpes, risk factors include any activity that exposes one to an infected patient’s saliva, for example, shared drinkware or cosmetics, or mouth to mouth contact.

The major risk factor for herpetic sycosis is close shaving with a razor blade in the presence of an acute orolabial infection.

Risk factors for herpes gladiatorum include participation in high-contact sports such as rugby, wrestling, MMA, and boxing.

Risk factors for herpetic whitlow include thumb sucking and nail biting in the presence of orolabial HSV-1 infection in the child population, and medical/dental profession in the adult population (although HSV-2 most commonly causes herpetic whitlow in adults). {3}

A major risk factor for herpes encephalitis is mutations in the toll-like receptor (TLR-3) or *UNC-93B* genes. It has been postulated that these mutations inhibit normal interferon-based responses.

The major risk factor for eczema herpeticum is skin barrier dysfunction. This can be seen in atopic dermatitis, Darier disease, Hailey-Hailey disease, mycosis fungoides, and all types of ichthyosis. The increased risk is also associated with mutations in the filaggrin gene, which is seen in atopic dermatitis and ichthyosis vulgaris. {4}

Risk factors for severe or chronic HSV infection include immunocompromised states such as transplant recipients (solid organ or hematopoietic stem cells), HIV infection, or leukemia/lymphoma patients.

Pathophysiology-

HSV-1 is typically spread through direct contact with contaminated saliva or other infected bodily secretions, as opposed to HSV-2, which is spread primarily by sexual contact. HSV-1 begins to replicate at the site of infection (mucocutaneous) and then proceeds to travel by retrograde flow down an axon to the dorsal root ganglia (DRG). It is in the DRG that latency is established {4}. This latency period allows the virus to remain in a non-infectious state for a variable amount of time before reactivation. HSV-1 is sly in its ability to evade the immune system via several mechanisms. One such mechanism is inducing an intercellular accumulation of CD1d molecules in antigen presenting cells {5}. Normally, these CD1d molecules are transported to the cell surface, where the antigen is presented resulting in the stimulation of natural killer T-cells, thus promoting immune response. When CD1d molecules are sequestered intercellularly, the immune response is inhibited. HSV-1 has several other mechanisms by which it down-regulates various immunologic cells and cytokines {6}

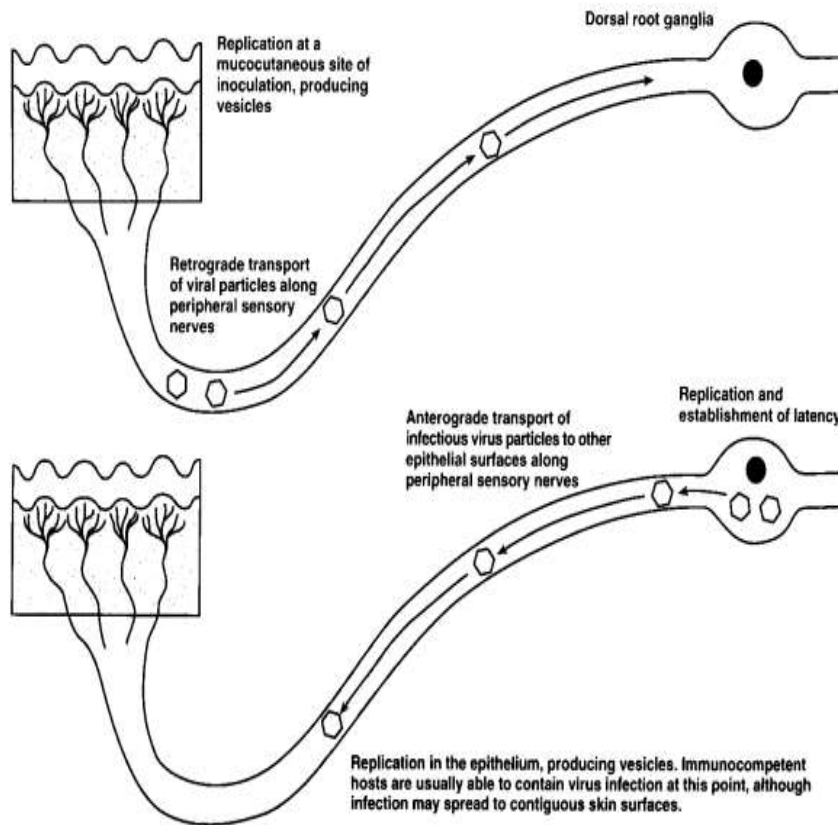


Figure 3. Schematic diagram of primary herpes simplex virus infection.

Source: Richard J. Whitley, David W. Kimberlin, Bernard Roizman [6]

Histopathology-

Histologic findings for HSV infection include ballooning degeneration of keratinocytes and multinucleated giant cells. Multinucleated keratinocytes may contain Cowdry A inclusions, which are eosinophilic nuclear inclusions that can also be seen in other herpesviruses such as varicella-zoster virus (VZV) and cytomegalovirus (CMV). [5]

Clinical features-

The incubation period ranges isolated, from 2 days to 12 days, with a mean of ~4 days. Primary HSV-1 infection results in oral shedding of virus in the mouth for as long as 23 days (mean, 7–10 days). Neutralizing antibodies appear between days 4 and 7 after the onset of disease, and 70% levels of these antibodies peak in ~3 weeks. Symptomatic disease in children is characterized by involvement of the buccal and gingival mucosa. The duration of illness is 2–3 weeks temperatures range from 101.7F to 104.7F. Children with symptomatic primary infection are often unable to swallow liquids because of the associated pain. Lesions within the mouth evolve from vesicles to shallow ulcerations on an erythematous base before healing [4]. Submandibular lymphadenopathy is common in patients with primary gingivostomatitis but rare in with recurrent infections. Other findings include sore throat mouth malaise, tender cervical lymphadenopathy, and inability to eat. [5]

A clinical distinction should be drawn between intraoral gingival lesions, indicative of presumed primary infection, and lip lesions indicative of recurrent infections. Pharyngitis is common, along with a mononucleosis-like syndrome, among patients with primary HSV infections that develop later in life. The onset of recurrent orolabial lesions is heralded by a prodrome of pain, burning, tingling, or itching, which generally lasts for 6 hours and is followed by the appearance of vesicles [12]. Vesicles appear most commonly at the vermilion border. Skin infections caused by HSV generally manifest as eczema herpeticum in patients with underlying atopic dermatitis. Infections of the digits, known as herpetic whitlow, are particularly common among medical and dental personnel

Diagnosis-

The gold standard for diagnosing HSV-1 infection is HSV-1 serology (antibody detection via western blot). The most sensitive and specific mechanism is viral polymerase chain reaction (PCR). However, serology remains the gold standard. Viral culture, direct fluorescent antibody (DFA) assay, and Tzanck smear are alternative methods of diagnosing [12]. It is important to note that the Tzanck smear identifies multinucleated giant cells, so it cannot distinguish between HSV and VZV

HSV-2

The sexually transmitted disease genital herpes is associated primarily with HSV-2. The virus is highly contagious and may be transmitted by individuals who are lifelong carriers but who remain asymptomatic (and may not even know they are infected). Infections are most often acquired through direct genital contact. Sexual practices involving oral-genital contact may be responsible for some crossover infections of HSV-1 to the genital area or of HSV-2 to the mouth and lips, while other crossover infections may be the result of self-infection through hand-genital-mouth contact.

Pathophysiology-

HSV-2 is transmitted through direct contact of sections in a seropositive individual who is actively shedding the virus. The virus preferentially affects the skin and mucous membranes with the virus invading epithelial cells on initial exposure and ultimately replicating intracellularly at that site. After the initial exposure and symptoms resolve, in 10 to 14 days, on average, the virus then lays dormant in the periaxonal sheath of the sensory nerves of either the trigeminal, cervical, lumbosacral, or autonomic ganglia. In these locations, the viral replication is often controlled by the patient's immune system and remains in a dormant state only to later reactive later in life{13}. When reactivation does occur, the virus travels through the sensory nerves until it reaches the mucocutaneous sites where replication then takes place and leads to vesicular clusters at the dermatological site of that sensory neuron.{14}

Histopathology-

Histological presentations of HSV-2 include the presence of dense lymphoid infiltrates with atypical lymphocytes. When looking at the surface of cells, it is common to see epidermal ballooning and acantholysis, which leads to the classic vesiculation seen on the clinical exam.{15}

Clinical features-

The incubation period for HSV-2 infection is usually four to five days but may be as short as 24 hours or as long as two weeks. The first symptoms may be pain or itching at the site of infection. This is followed within a day or two by the appearance of blister like lesions that may occur singly or in groups. In males the common sites of infection include the foreskin, the glans, and the shaft of the penis. In females the blister may occur on the labia, the clitoris, the opening of the vagina, or, occasionally, the uterine cervix. Within a few days the blisters rupture and merge to form large areas of denuded tissue surrounded by swollen, inflamed skin {4}. At this stage the lesions may become acutely painful with intense burning and irritation. In females especially, urination may cause great discomfort. Generalized symptoms such as fever and malaise may develop, and lymph nodes in the groin may enlarge. Lesions may persist in this stage for a week or more, and complete healing may take four to six weeks{5}. Genital herpes is generally more severe in females and may become so uncomfortable and disabling as to require hospitalization. Recurrences are not uncommon and may be associated with emotional stress, trauma, sexual intercourse, other infections, or menstruation. Symptoms may not be as severe in recurrent infections as in the initial one.{12}

Diagnosis-

The Pap smear and Giemsa smear are two techniques commonly used to diagnose genital herpes.{7}

Treatment-

Acyclovir (9-[2-hydroxyethoxymethyl] guanine), a synthetic acyclic purine nucleoside analogue, has become the standard with of therapy for HSV infections. It is the most widely scribed and clinically effective antiviral drug available to date{8}.The prodrug valacyclovir (converted to acyclovir) and famciclovir (converted to penciclovir) have recently been licensed and have greater oral bioavailability than acyclovir and pen- Prevention of HSV Infections ciclovir.

REFERENCES:

- [1] Rechenchoski DZ, Faccin-Galhardi LC, Linhares REC, Nozawa C. Herpesvirus: an underestimated virus. *Folia Microbiol (Praha)*. 2017 Mar;62(2):151-156. [[PubMed](#)]
- [2] Soriano V, Romero JD. Rebound in Sexually Transmitted Infections Following the Success of Antiretrovirals for HIV/AIDS. *AIDS Rev*. 2018;20(4):187-204. [[PubMed](#)]
- [3] Mostafa HH, Thompson TW, Konen AJ, Haenchen SD, Hilliard JG, Macdonald SJ, Morrison LA, Davido DJ. Herpes Simplex Virus 1 Mutant with Point Mutations in *UL39* Is Impaired for Acute Viral Replication in Mice, Establishment of Latency, and Explant-Induced Reactivation. *J Virol*. 2018 Apr 01;92(7) [[PMC free article](#)] [[PubMed](#)]
- [4] Pfaff F, Groth M, Sauerbrei A, Zell R. Genotyping of herpes simplex virus type 1 by whole-genome sequencing. *J Gen Virol*. 2016 Oct;97(10):2732-2741. [[PubMed](#)]
- [5] van Oeffelen L, Biekram M, Poeran J, Hukkelhoven C, Galjaard S, van der Meijden W, Op de Coul E. Update on Neonatal Herpes Simplex Epidemiology in the Netherlands: A Health Problem of Increasing Concern? *Pediatr Infect Dis J*. 2018 Aug;37(8):806-813. [[PubMed](#)]
- [6] Rosenberg J, Galen BT. Recurrent Meningitis. *Curr Pain Headache Rep*. 2017 Jul;21(7):33. [[PubMed](#)]

- [7] Cruz AT, Freedman SB, Kulik DM, Okada PJ, Fleming AH, Mistry RD, Thomson JE, Schnadower D, Arms JL, Mahajan P, Garro AC, Pruitt CM, Balamuth F, Uspal NG, Aronson PL, Lyons TW, Thompson AD, Curtis SJ, Ishimine PT, Schmidt SM, Bradin SA, Grether-Jones KL, Miller AS, Louie J, Shah SS, Nigrovic LE., HSV Study Group of the Pediatric Emergency Medicine Collaborative Research Committee. Herpes Simplex Virus Infection in Infants Undergoing Meningitis Evaluation. *Pediatrics*. 2018 Feb;141(2) [[PMC free article](#)] [[PubMed](#)]
- [8] Zhang J, Liu H, Wei B. Immune response of T cells during herpes simplex virus type 1 (HSV-1) infection. 2017 Apr. *J Zhejiang Univ Sci B*. 18(4):277-288. [[PMC free article](#)] [[PubMed](#)]
- [9] Giraldo D, Wilcox DR, Longnecker R. The Type I Interferon Response and Age-Dependent Susceptibility to Herpes Simplex Virus Infection. *DNA Cell Biol*. 2017 May;36(5):329-334. [[PMC free article](#)] [[PubMed](#)]
- [10] Rajasagi NK, Rouse BT. Application of our understanding of pathogenesis of herpetic stromal keratitis for novel therapy. *Microbes Infect*. 2018 Oct - Nov;20(9-10):526-530. [[PMC free article](#)] [[PubMed](#)]
- [11] Bin L, Li X, Richers B, Streib JE, Hu JW, Taylor P, Leung DYM. Ankyrin repeat domain 1 regulates innate immune responses against herpes simplex virus 1: A potential role in eczema herpeticum. *J Allergy Clin Immunol*. 2018 Jun;141(6):2085-2093.e1. [[PMC free article](#)] [[PubMed](#)]
- [12] Spruance ST, Overall JC Jr, Kern ER. The natural history of recurrent conflict of interest. herpes simplex labialis—implications for antiviral therapy. *N Engl J Med* 1977;297:69–7
- [13] Fatahzadeh M, Schwartz RA. Human herpes simplex virus infections: epidemiology, pathogenesis, symptomatology, diagnosis, and management. *J Am Acad Dermatol*. 2007 Nov;57(5):737-63; quiz 764-6. [[PubMed](#)]
- {14} Leinweber B, Kerl H, Cerroni L. Histopathologic features of cutaneous herpes virus infections (herpes simplex, herpes varicella/zoster): a broad spectrum of presentations with common pseudolymphomatous aspects. *Am J Surg Pathol*. 2006 Jan;30(1):50-8. [[PubMed](#)]
- {15} Böer A, Herder N, Winter K, Falk T. Herpes folliculitis: clinical, histopathological, and molecular pathologic observations. *Br J Dermatol*. 2006 Apr;154(4):743-6. [[PubMed](#)]
- {15} Böer A, Herder N, Winter K, Falk T. Herpes folliculitis: clinical, histopathological, and molecular pathologic observations. *Br J Dermatol*. 2006 Apr;154(4):743-6. [[PubMed](#)]

